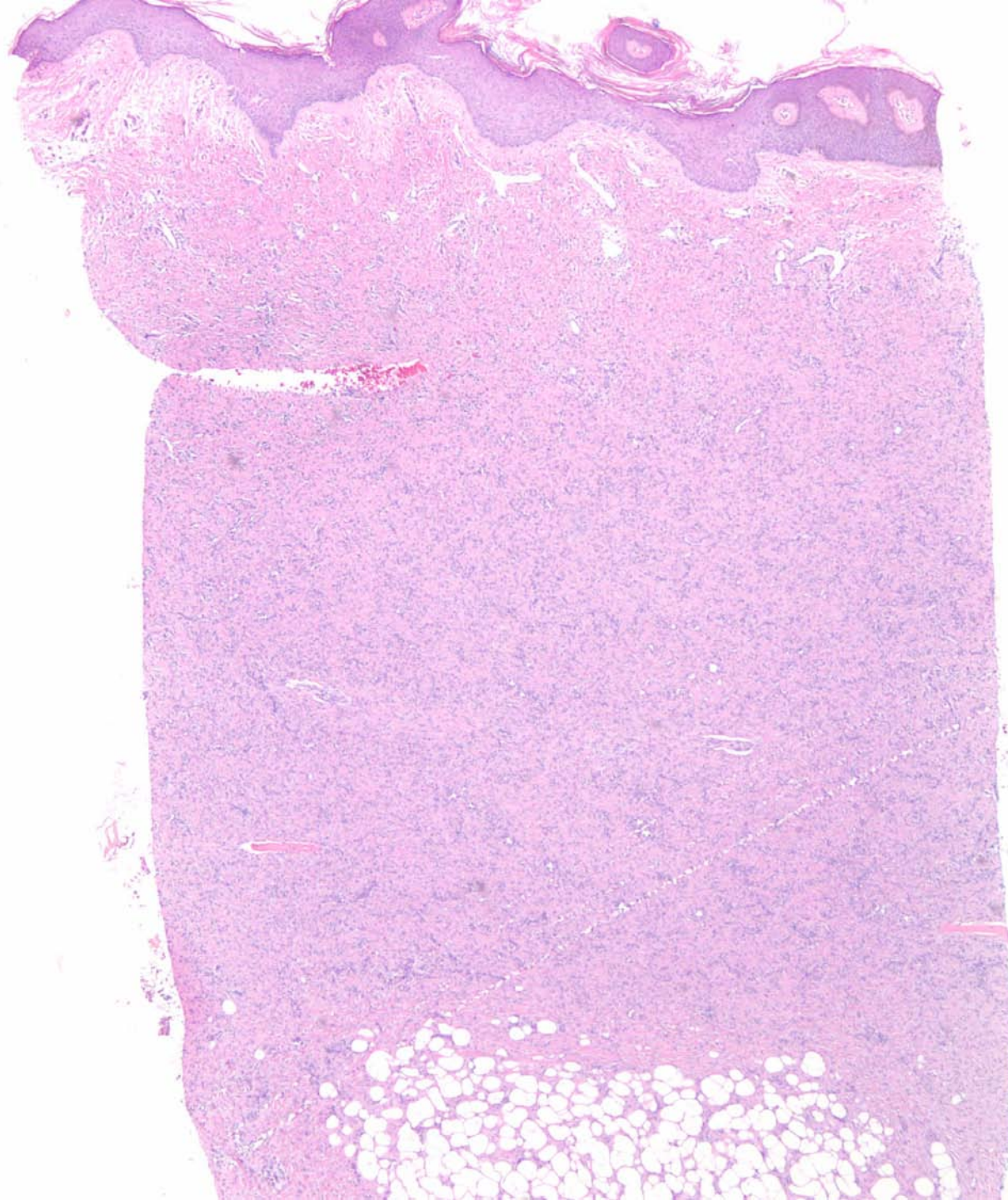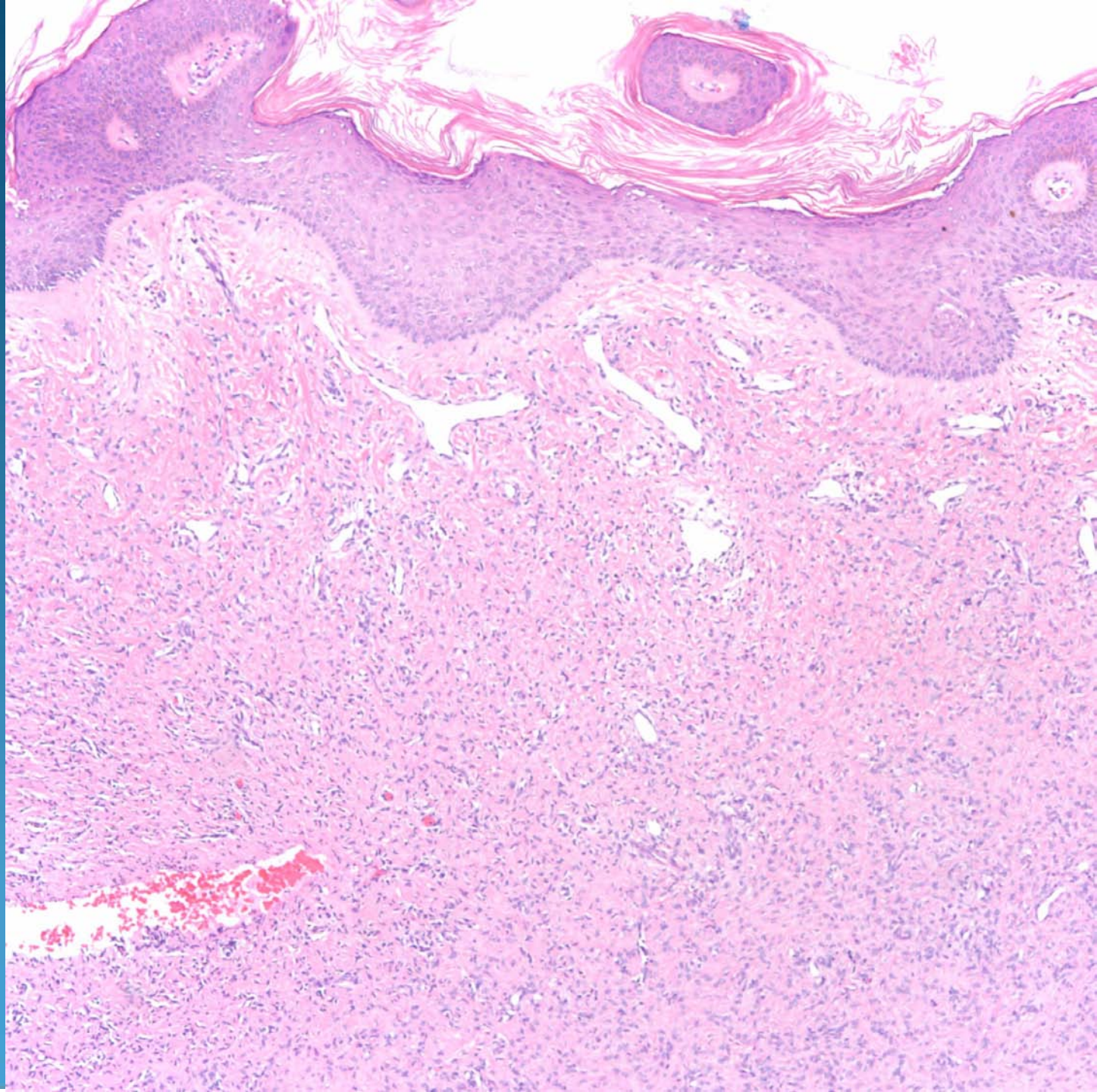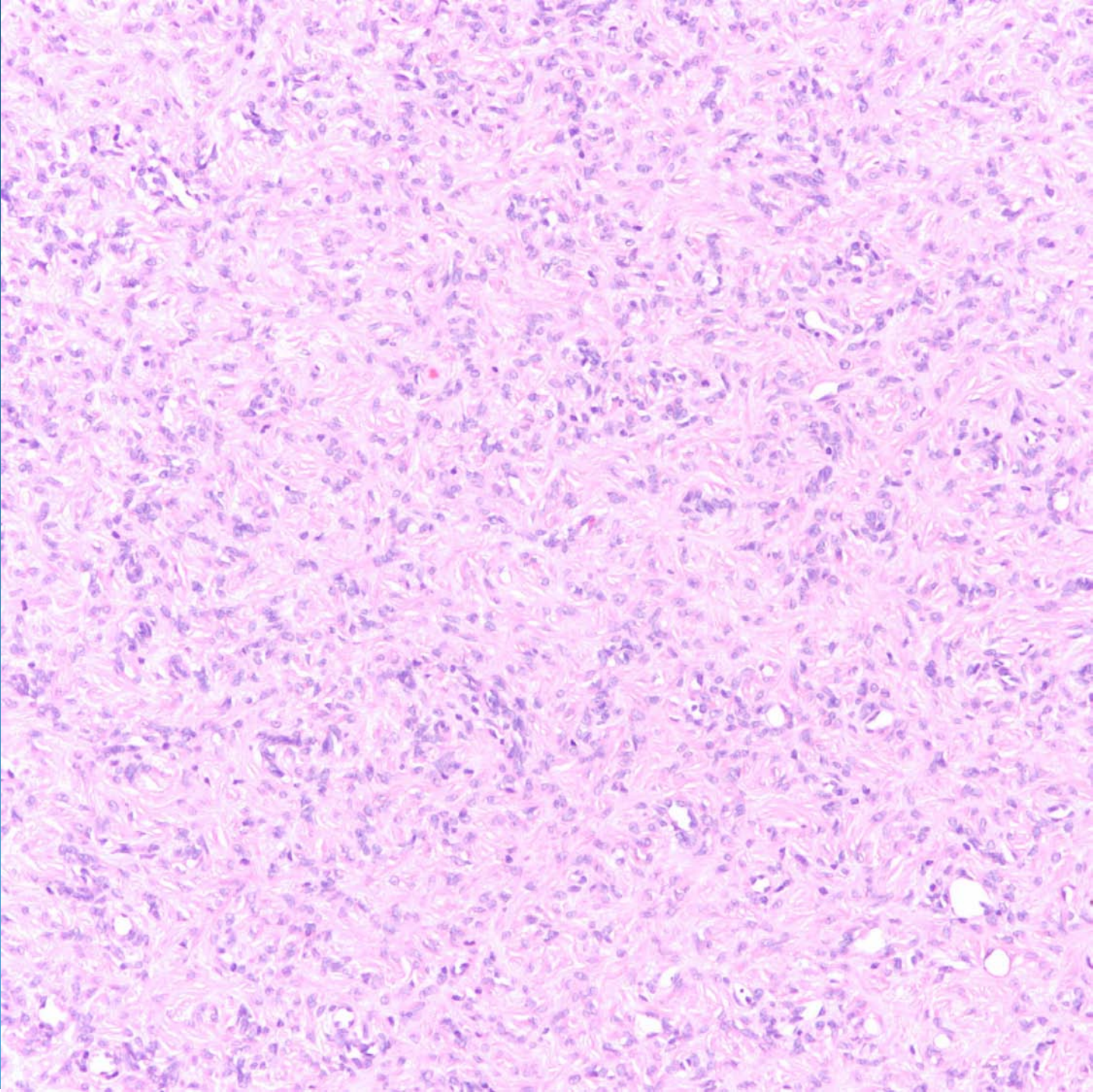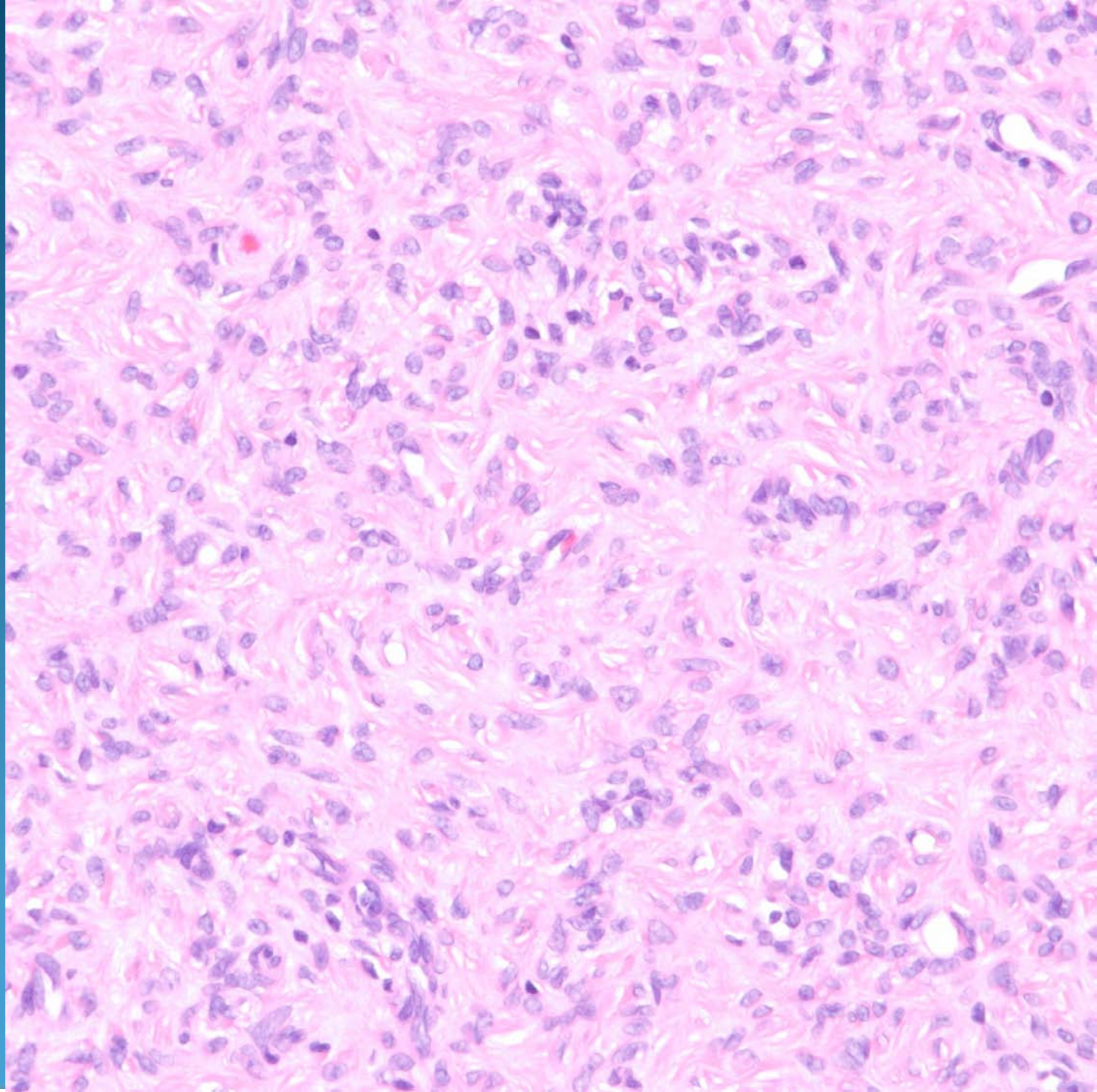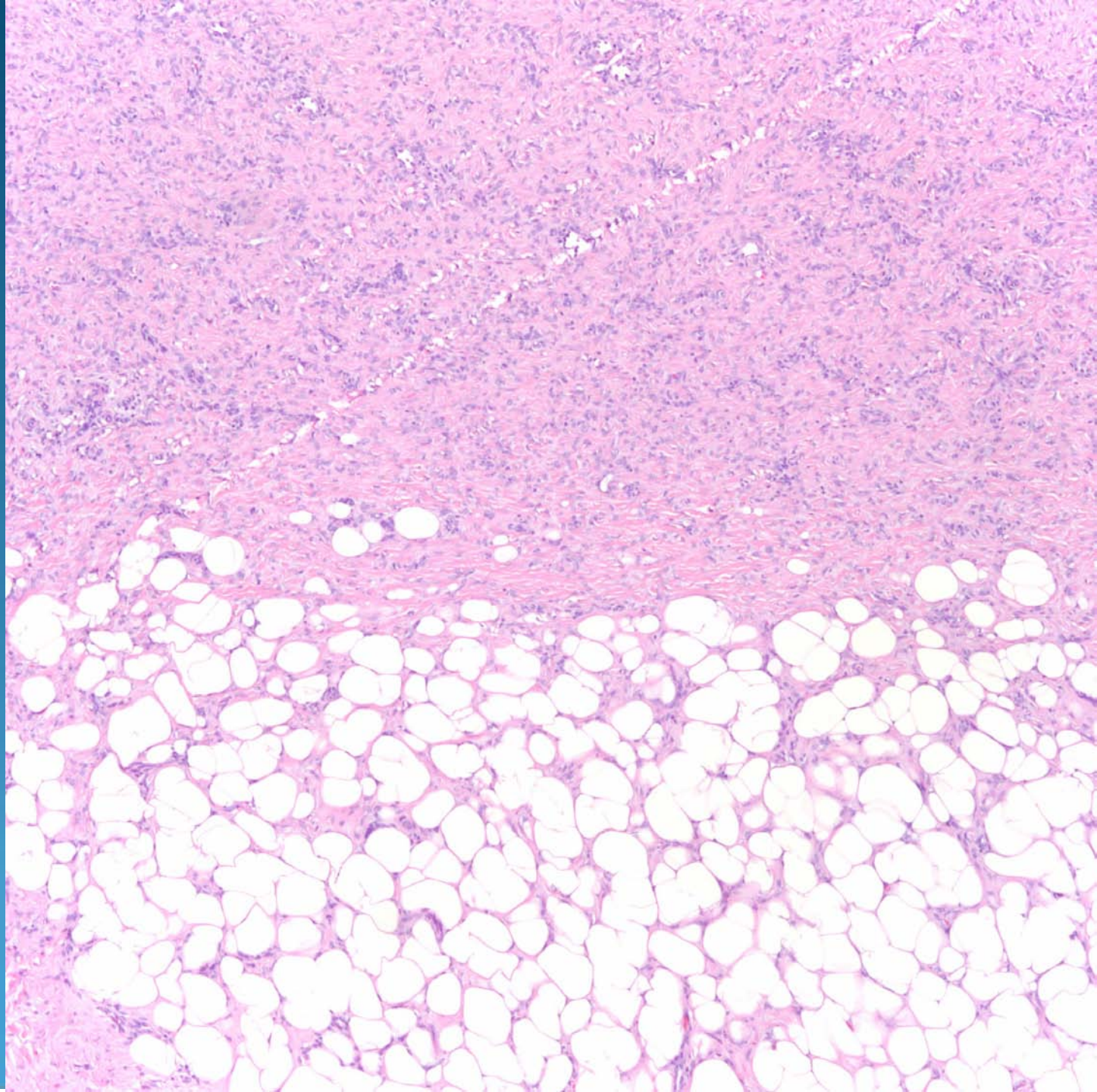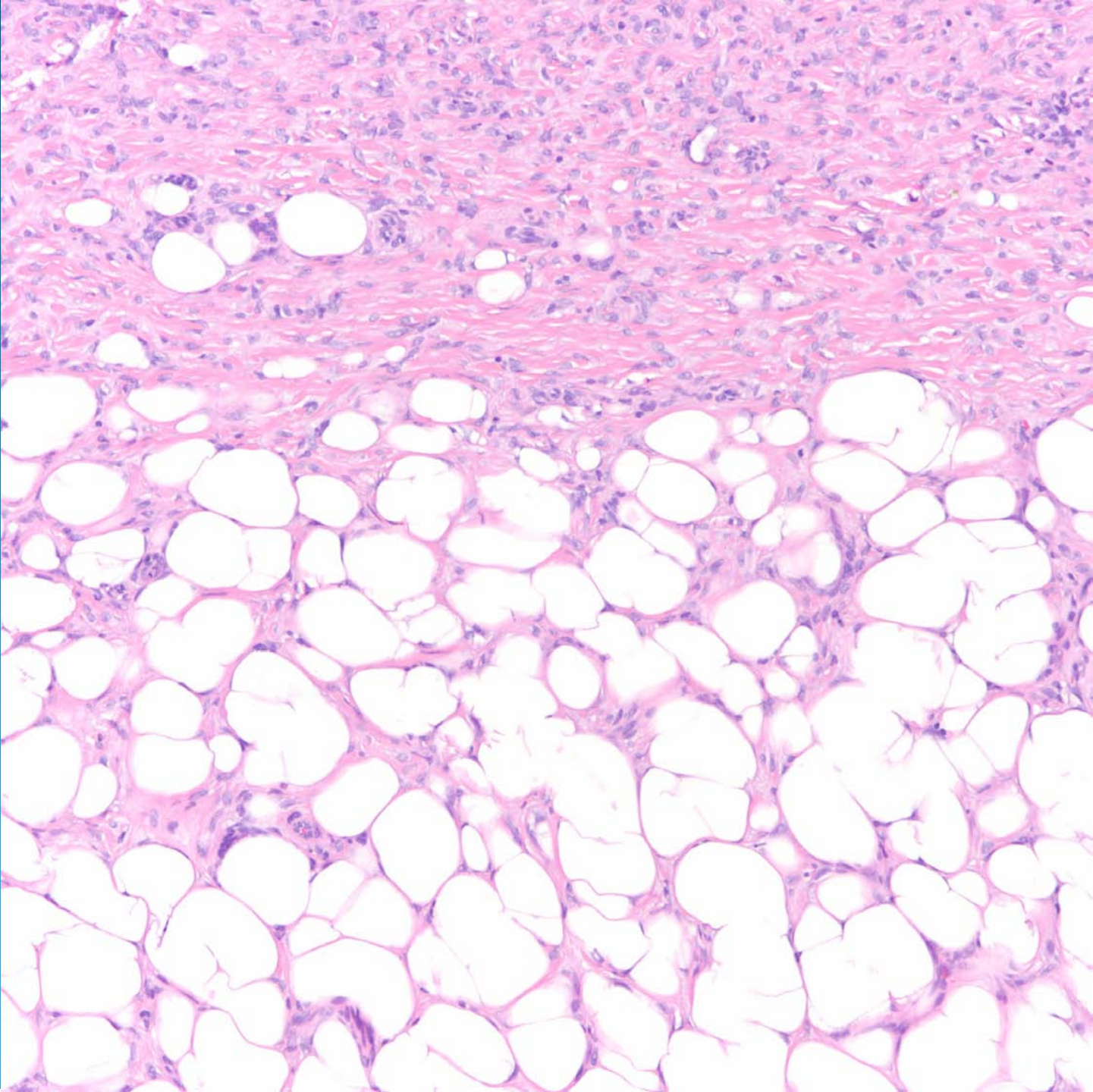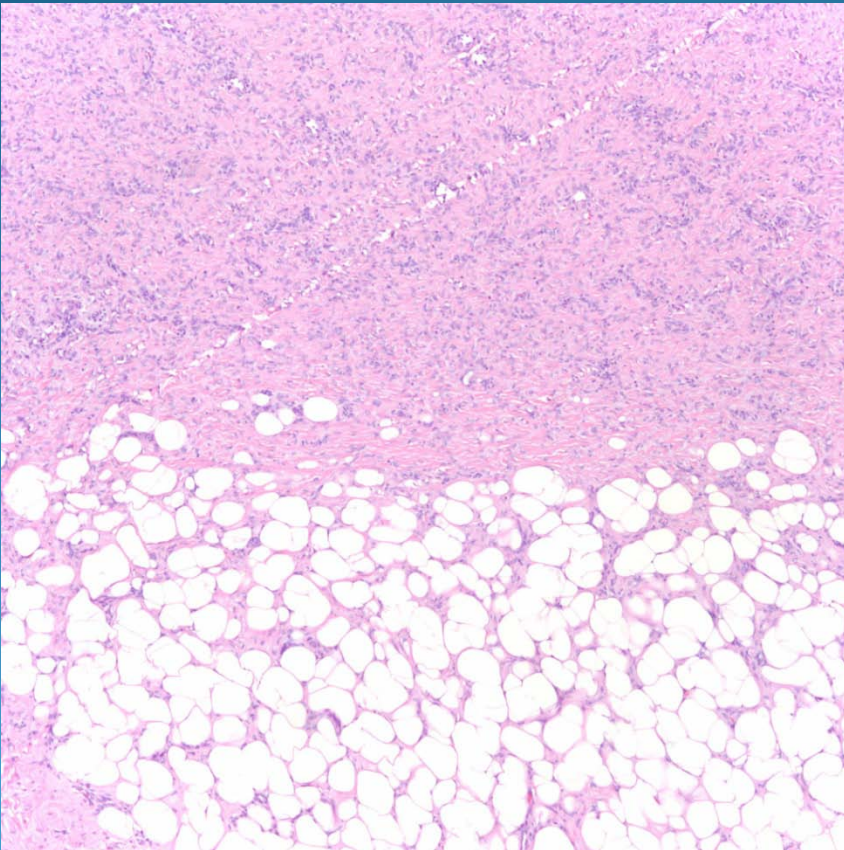


Dermatofibroma

Pearls



- Cellular spindle cell tumor in dermis separated from epidermis by a Grenz zone
- May see hyperplastic epidermis with follicular induction
- Note the “root-like” extension of the spindle cells with the fat, contrasting with the “Swiss-cheese” pattern of spindle cells and fat with DFSP